

# **Radiographic Techniques 2**

## **lecture 11**

### **Sacrum & Coccyx**

**By**

**Ali Hani Kareem**

**Master of Radiography Techniques /2021**

## Sacrum (1) -posterior/postero-anterior

\*The sacrum may be either imaged antero-posteriorly (**AP**) or postero-anteriorly (**PA**).

\*If imaged **PA**, there will be various **advantages**, including a lower dose to the gonads and better demonstration of the sacro-iliac joints, as the joint spaces will be more parallel with the divergent central ray.

\*The **AP** position may be a more realistic option when the patient is **infirm** or **injured** and therefore would find it difficult to maintain the prone position.

### Position of patient and image receptor

- The patient lies **supine** or **prone** on the Bucky table, with the **median sagittal plane** coincident with, and at **right-angles** to, the midline of the Bucky.
- The anterior superior iliac spines should be equidistant from the tabletop.
- If the patient is examined supine (AP), the **knees can be flexed** over a foam pad for **comfort**. This will also **reduce** the **pelvic tilt**.
- **The image receptor** is displaced cranially for **AP** projection, or caudally for **PA** projections, such that its centre coincides with the angled central ray.

### Direction and location of the X-ray beam

#### 1. Antero-posterior:

- a. **Direction** of the X-ray beam the collimated central beam is directed 10–25° cranially from the vertical.

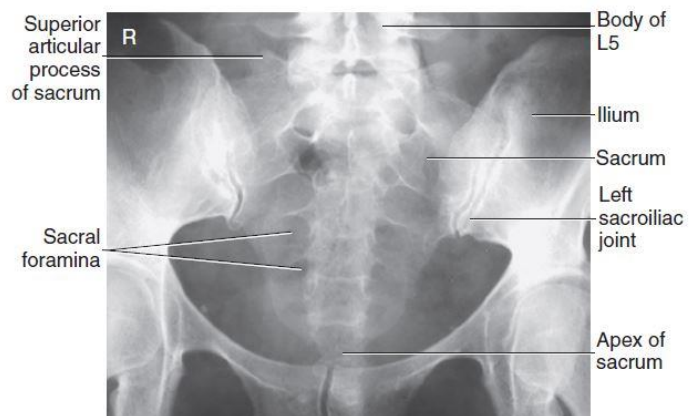
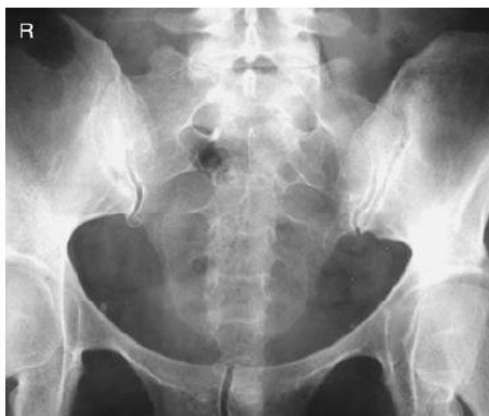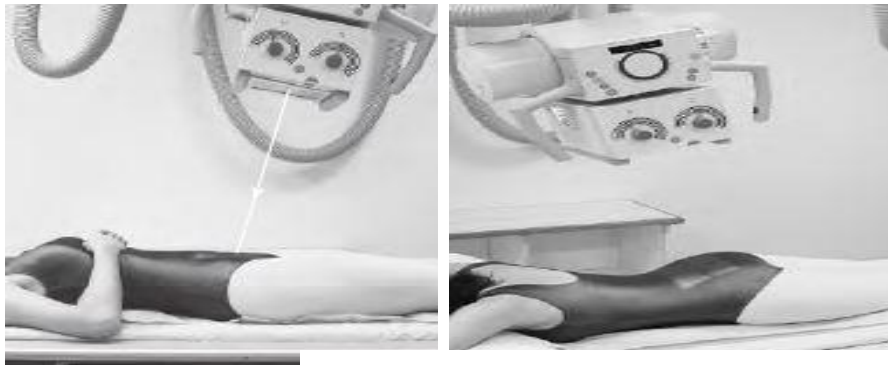**b. Location (center)** to point midway between the level of the anterior superior iliac spines and the superior border of the symphysis pubis (**to the middle of the sacrum**).

**\*The degree of angulation** of the central ray is normally **greater** for **females** than for **males** and will be reduced for a greater degree of flexion at the hips and knees.

## 2. Postero–anterior:

**a. Direction** the degree of beam angulation will depend on the pelvic tilt. Palpate the sacrum and then simply **apply a caudal angulation**, such that the central ray is perpendicular to the long axis of the sacrum.

**b. Location (center)** palpate the position of the sacrum by locating the posterior superior iliac spine and coccyx. **Centre to the middle of the sacrum**.



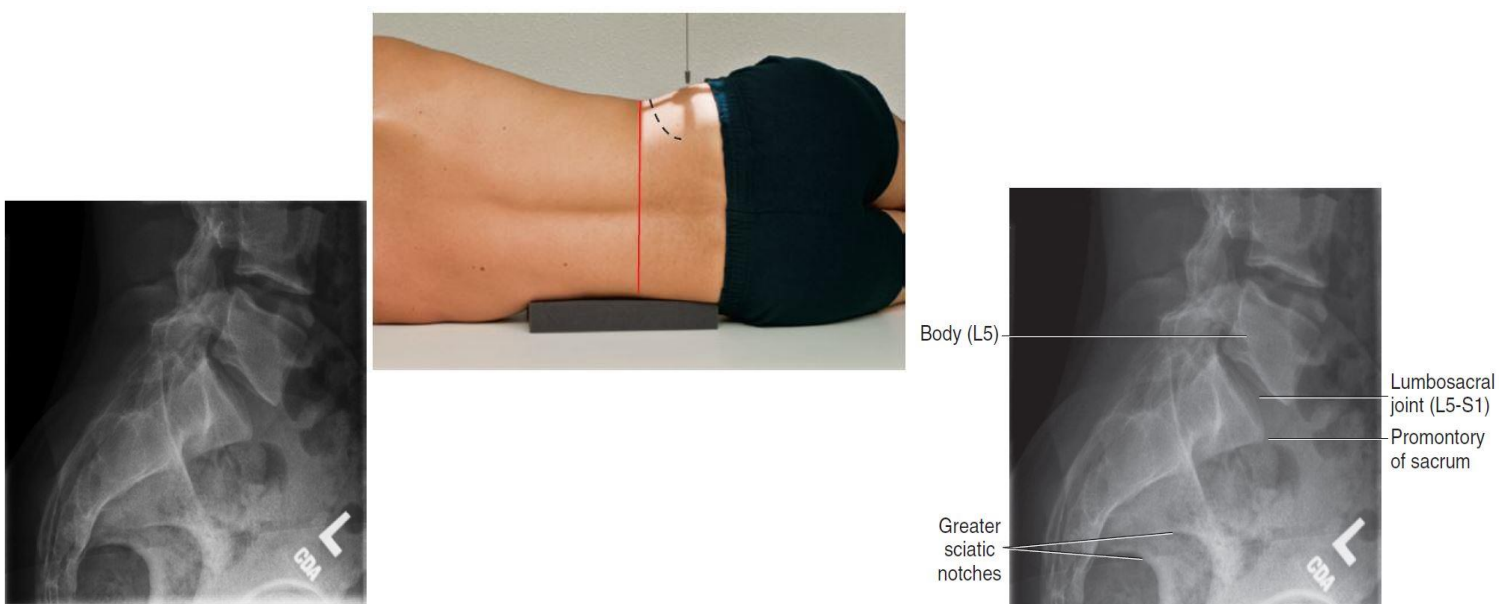
## (2) Lateral

### Position of patient and image receptor

- The patient lies on either side on the Bucky table with the arms raised and the hands resting on the pillow. The knees and hips are flexed slightly for stability.
- The dorsal aspect of the trunk should be at right-angles to the image receptor. This can be assessed by palpating the iliac crests or the posterior superior iliac spines. with the median sagittal plane parallel to, the midline of the Bucky.
- The image receptor is centred to coincide with the central ray at the level of the midpoint of the sacrum.

### Direction and location of the X-ray beam

- Direction** the collimated vertical beam is directed at right-angles to the long axis of the sacrum.
- Location (center)** to the middle of the sacrum.



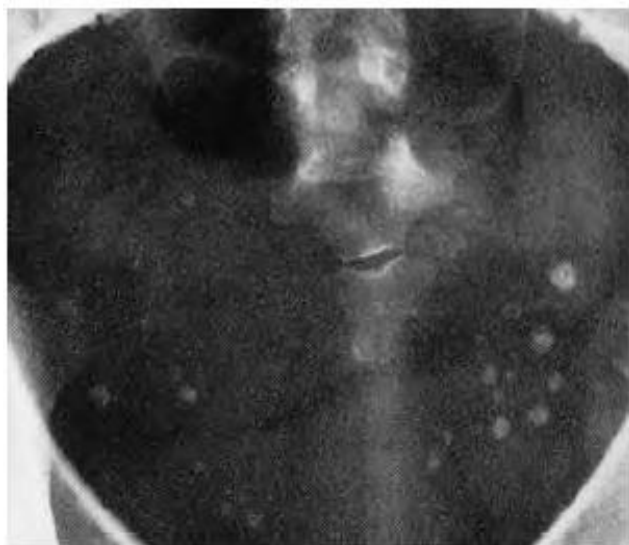
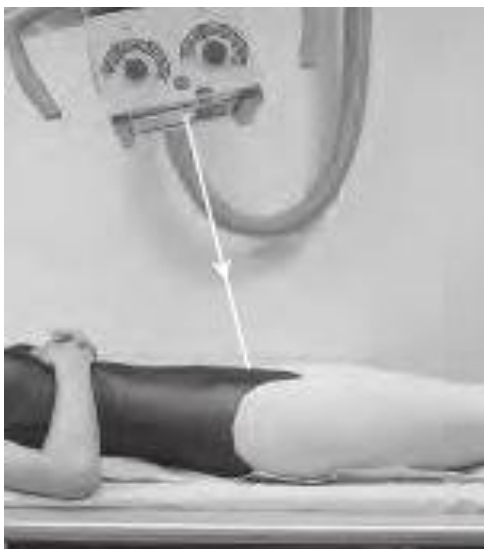## Coccyx (1) Antero-posterior (Basic)

### Position of patient and image receptor

- The patient lies supine on the Bucky table, with the median sagittal plane coincident with, and at right-angles to, the midline of the Bucky.
- The anterior superior iliac spines should be equidistant from the tabletop.
- The knees can be flexed over a foam pad for comfort and to reduce the **pelvic tilt**.
- The image receptor is displaced **caudally** so that its centre coincides with the central ray.

### Direction and location of the X-ray beam

- Direction of the X-ray beam:** the collimated beam is directed **15° caudally**
- Location (center)** to a point in the midline **2.5 cm superior to the symphysis pubis**.



## (2) Lateral

### Position of patient and image receptor

- The patient lies on either side on the Bucky table, with the palpable coccyx in the midline of the Bucky. The arms are raised, with the hands resting on the pillow. The knees and hips are flexed slightly for stability.
- The dorsal aspect of the trunk should be at right-angles to the image receptor. This can be assessed by palpating the iliac crests or the posterior superior iliac spines. The **median sagittal plane** should be **parallel** with the Bucky.
- The **image receptor is centred** to coincide with the central ray **at the level of the coccyx**.

### Direction and location of the X-ray beam

- Direction of the X-ray beam:** collimated vertical beam
- Location (center)** to a point at right-angles to the long axis of the sacrum and **at the level of the coccyx**.

